



Muscle Tissue

仇文颖, 陈咏梅, 钱晓菁

Dept. of Anatomy, Histology & Embryology

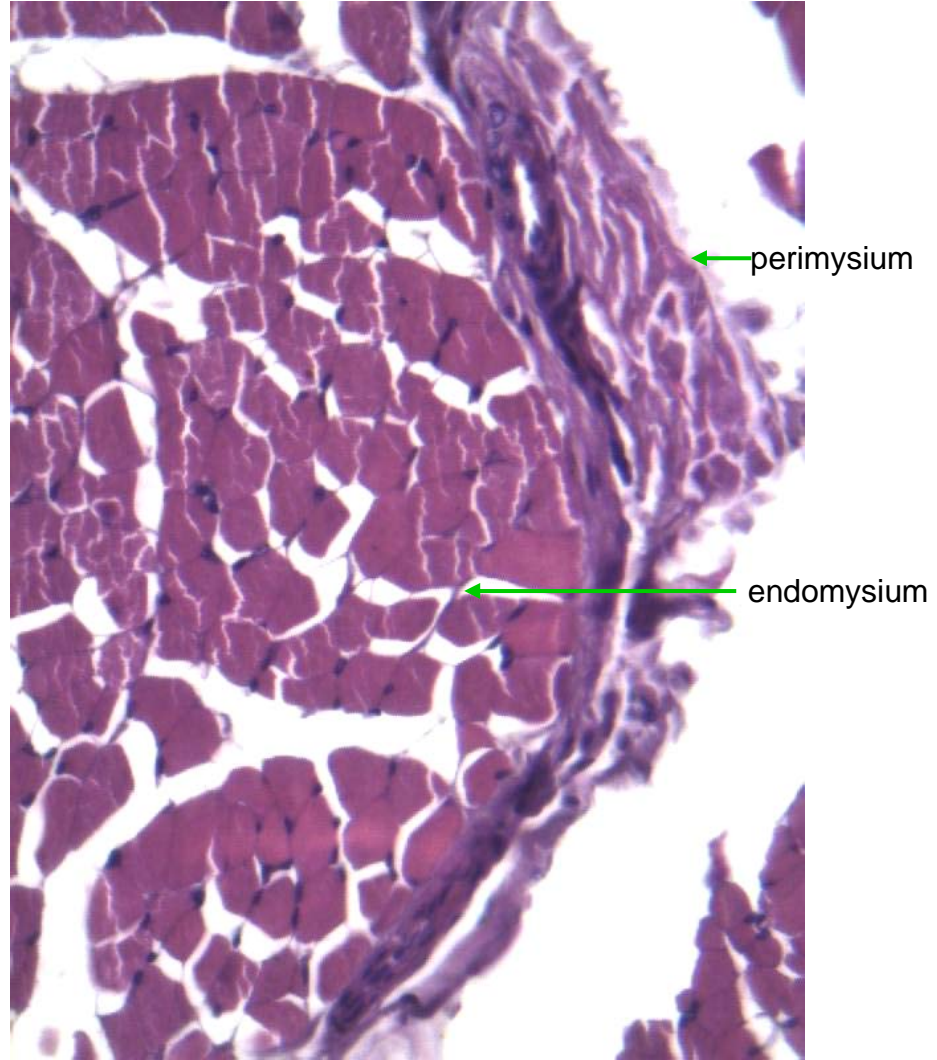
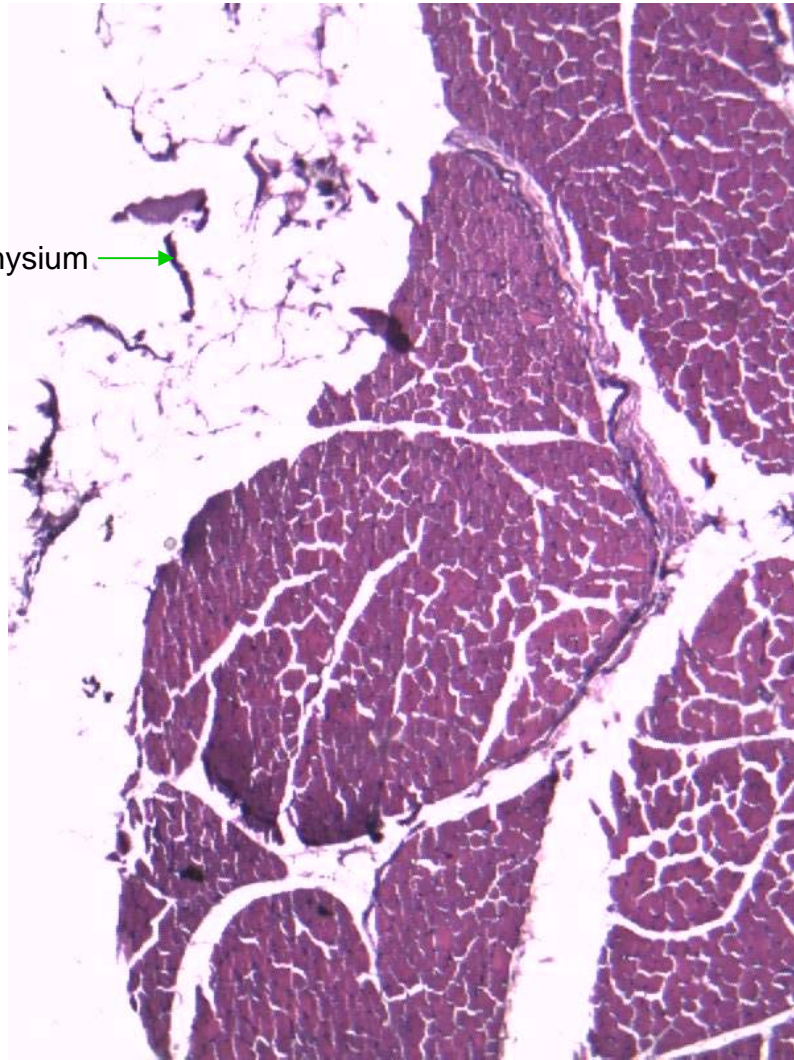
Peking Union Medical College

Objectives

- Be able to identify and describe in detail the three basic type of muscle, including the following characteristics:
 - 1) relative size and shape of fibers;
 - 2) location of nuclei and relative number per cell or fiber;
 - 3) the presence or absence of cross-striations;
 - 4) the presence or absence special features, e.g., intercalated discs, branching of cells or fibers.
- Identification of the sarcolemma, sarcoplasm and myofibrils.
- The structure of a sarcomere and the morphologic changes occurring in it during contraction.

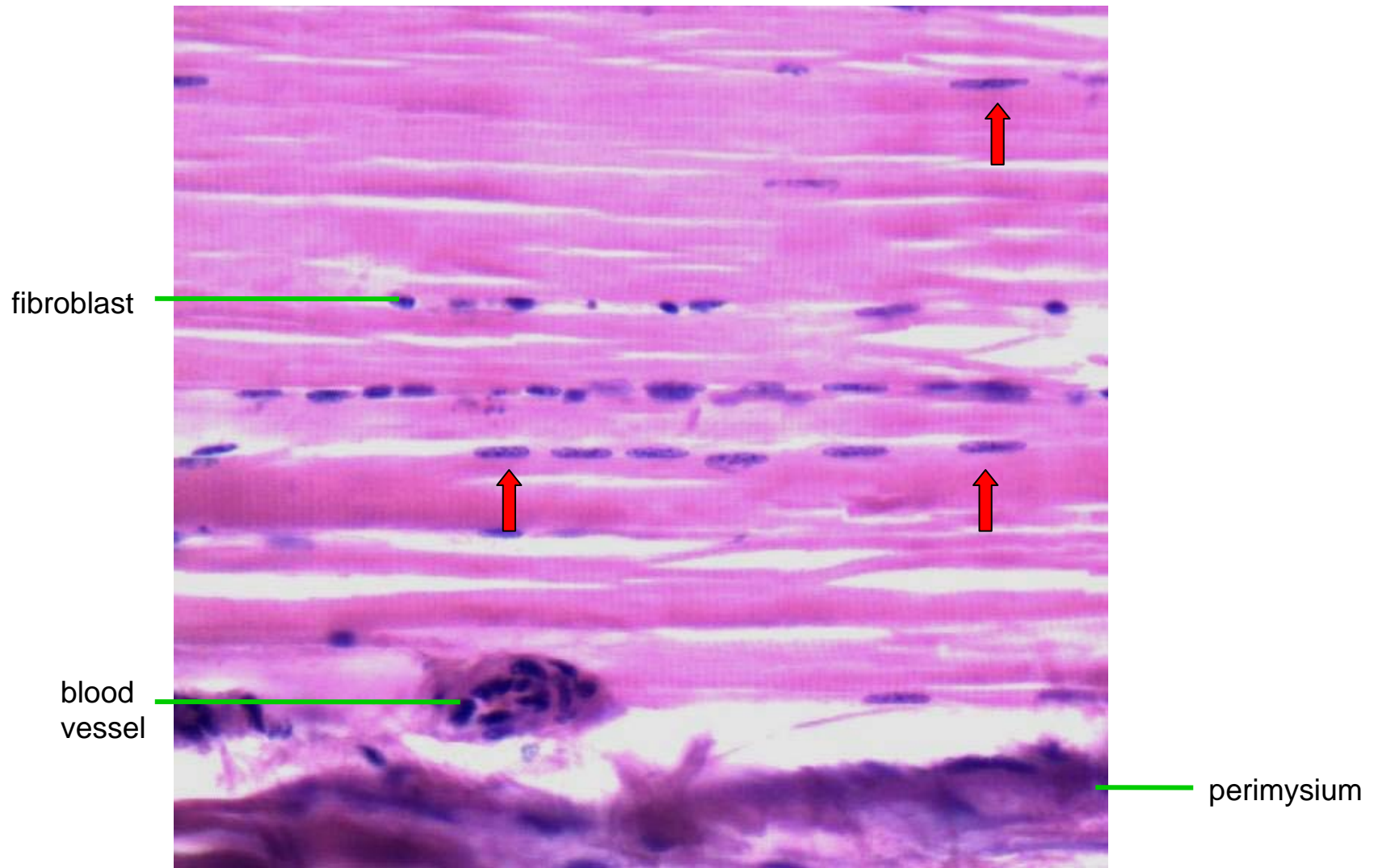
1. Striated muscle

No. M2 (CS) HE



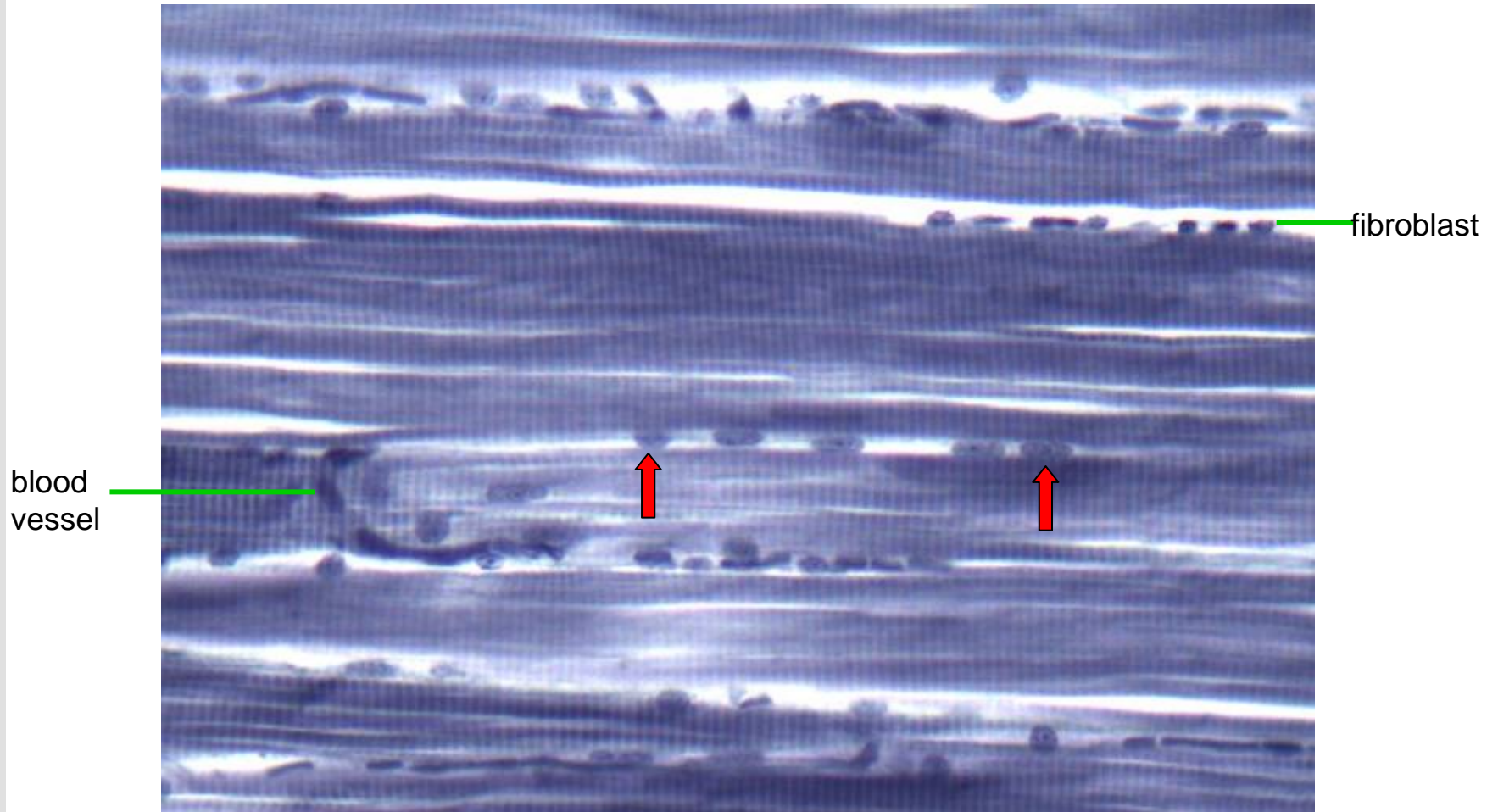
1. Striated muscle

No. M4 (LS) HE




1. Striated muscle

No. M1 IH

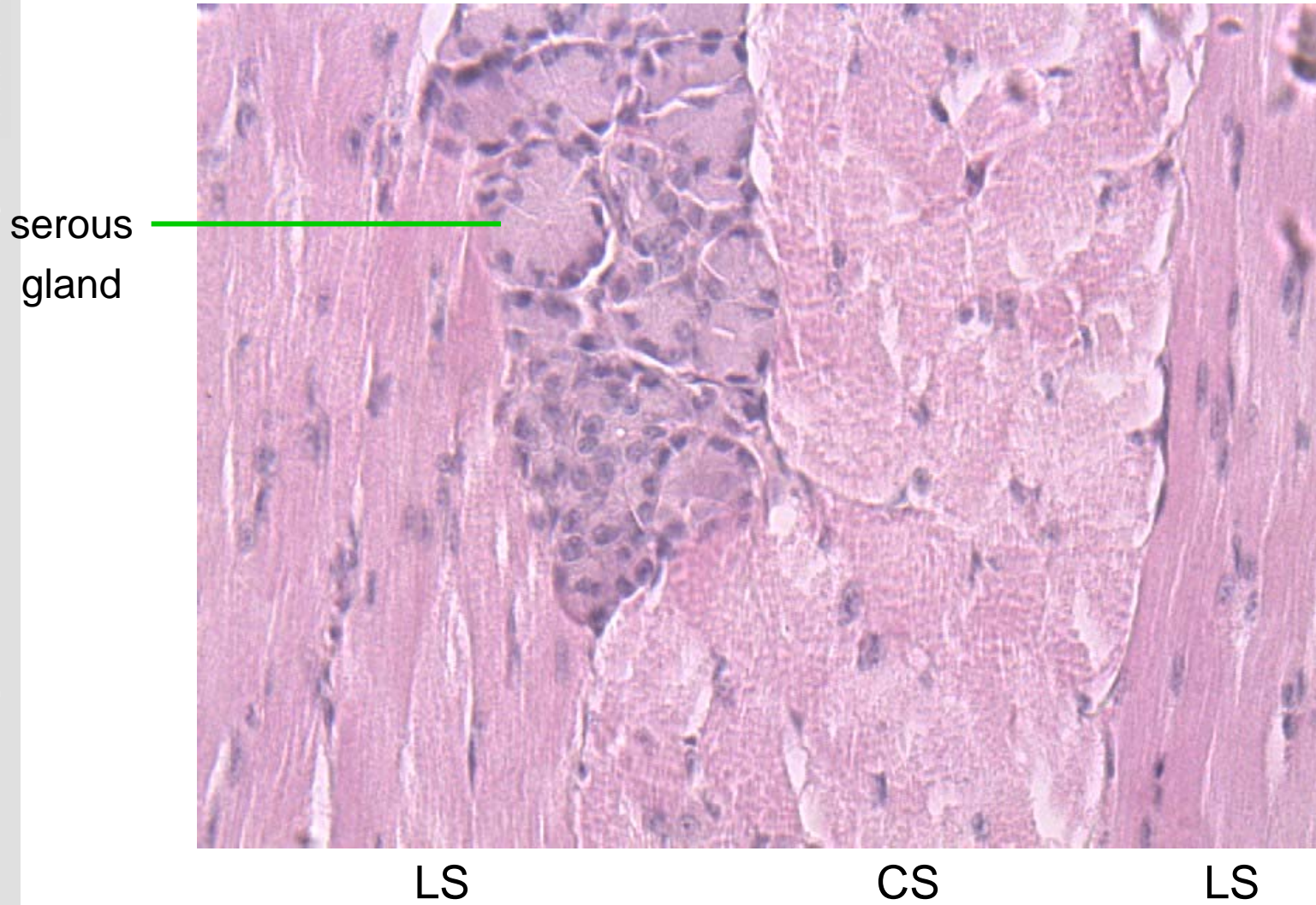


Demonstration: Z line



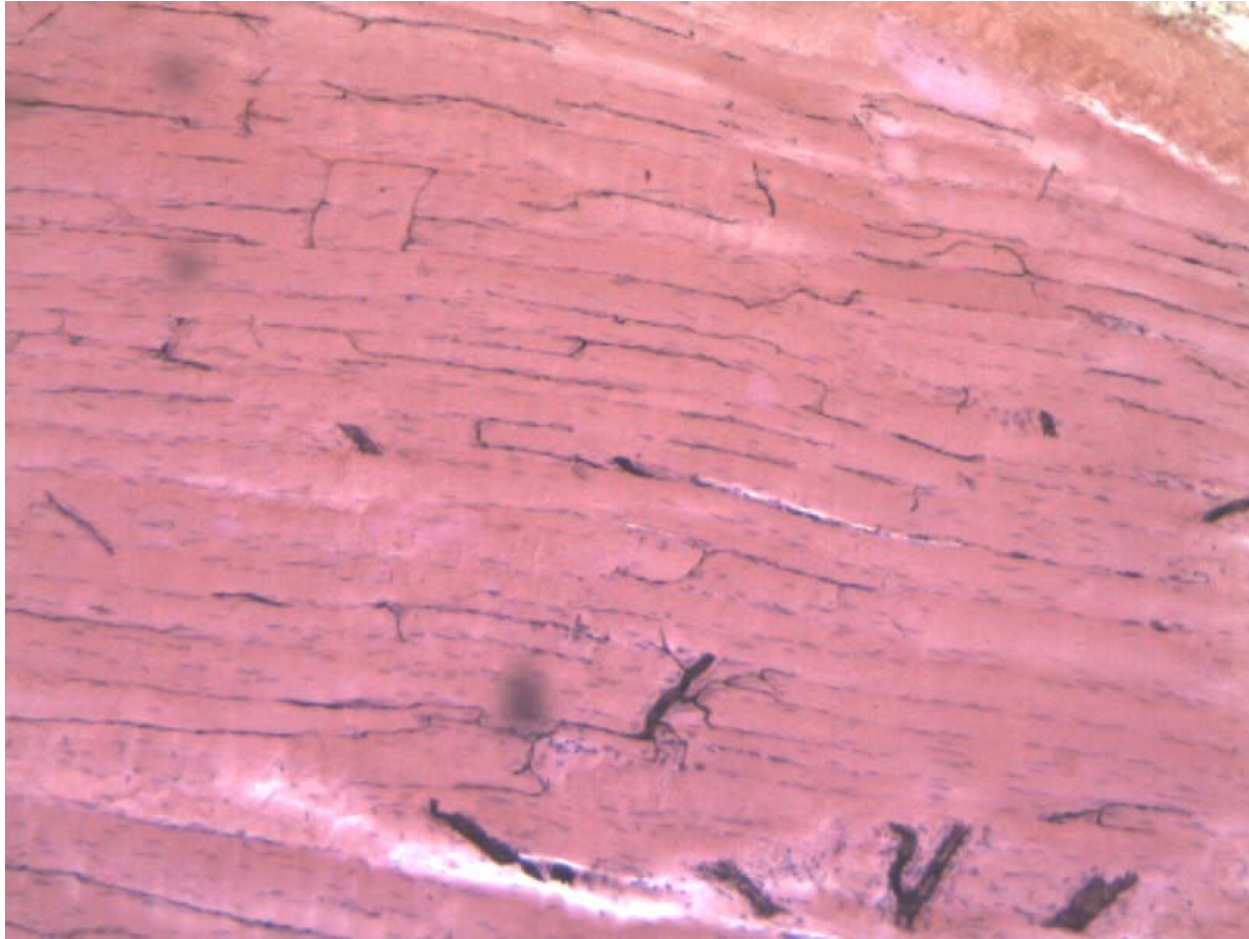
1. Striated muscle

No. DT2 Tongue HE



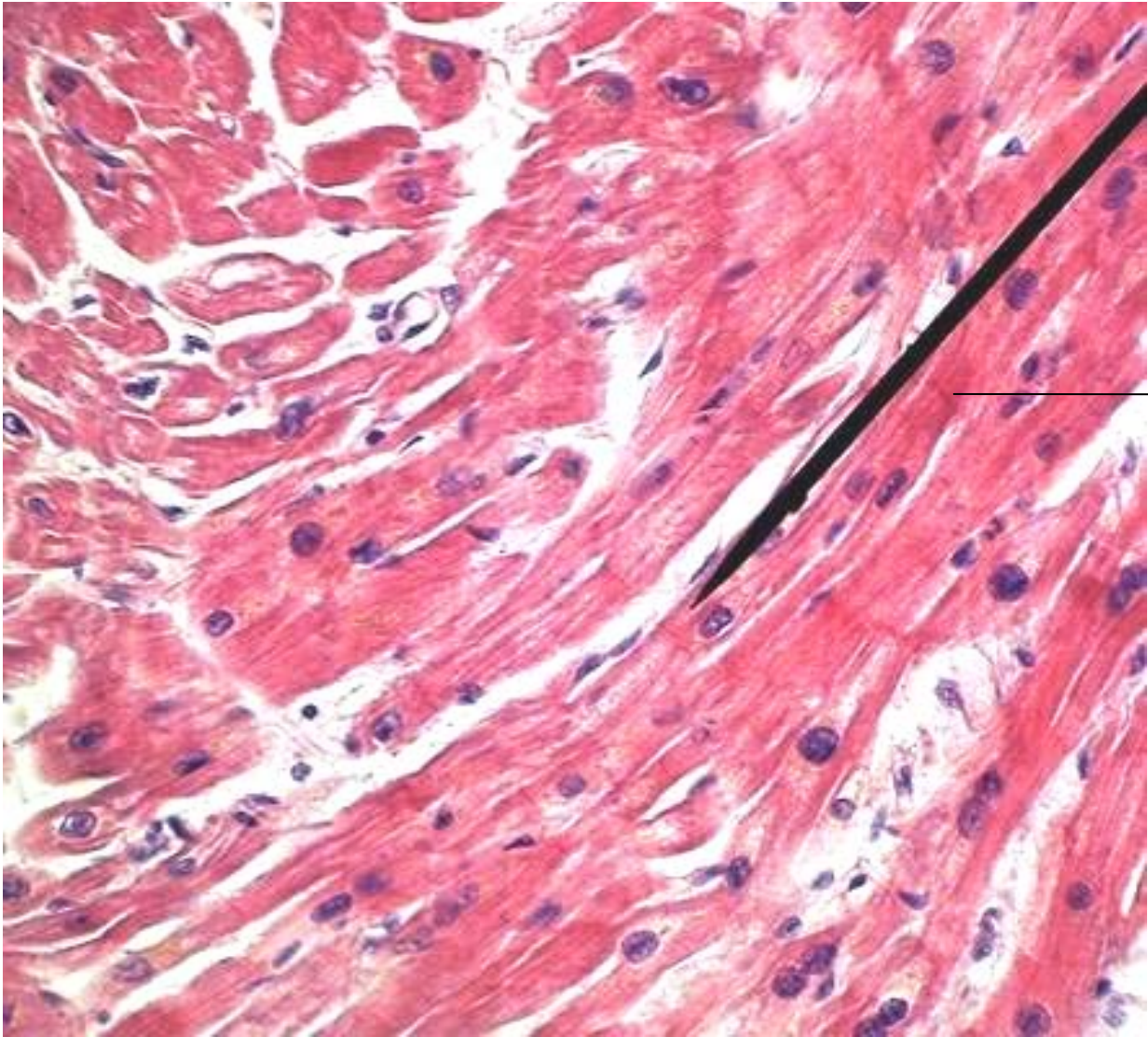
Demonstration: injected blood vessels

Ocular muscle, Rabbit, Indian ink injection



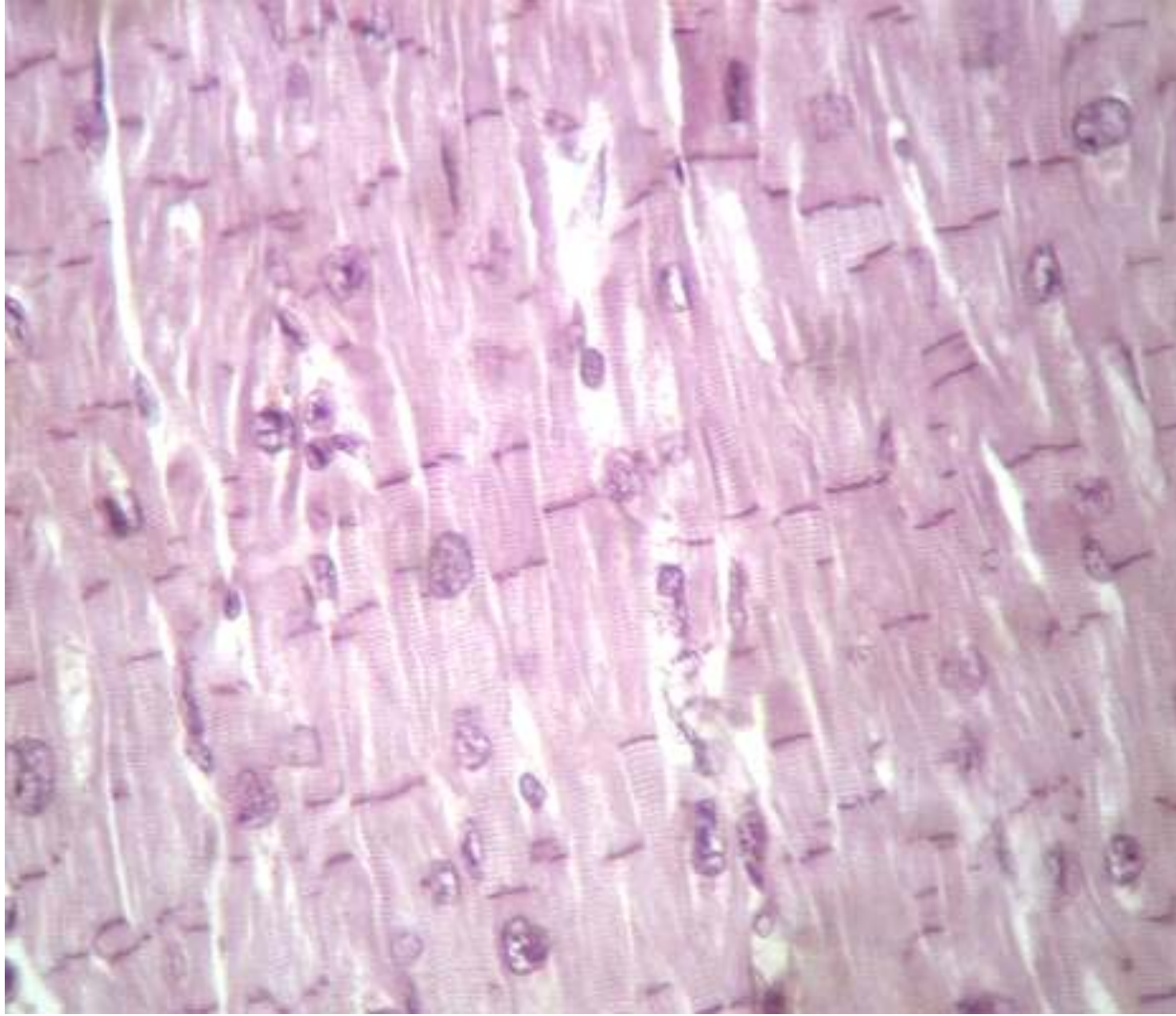
2. Cardiac muscle

No.M3 Heart HE



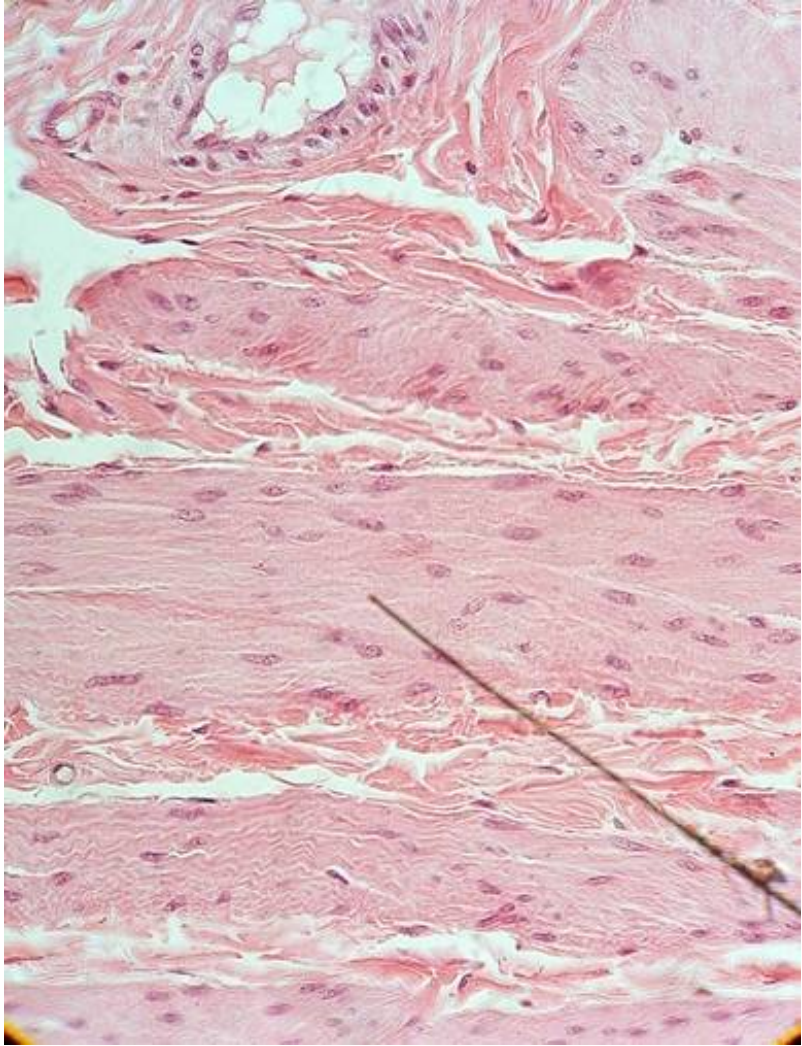
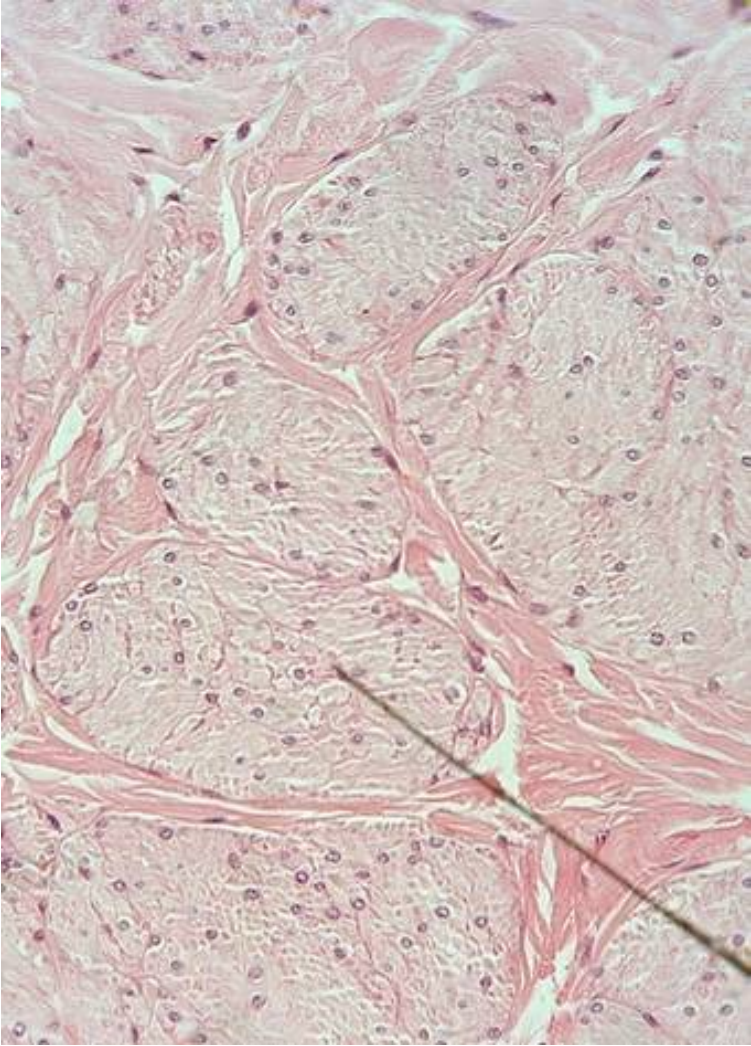
Intercalated disk

Demonstration: Intercalated disk



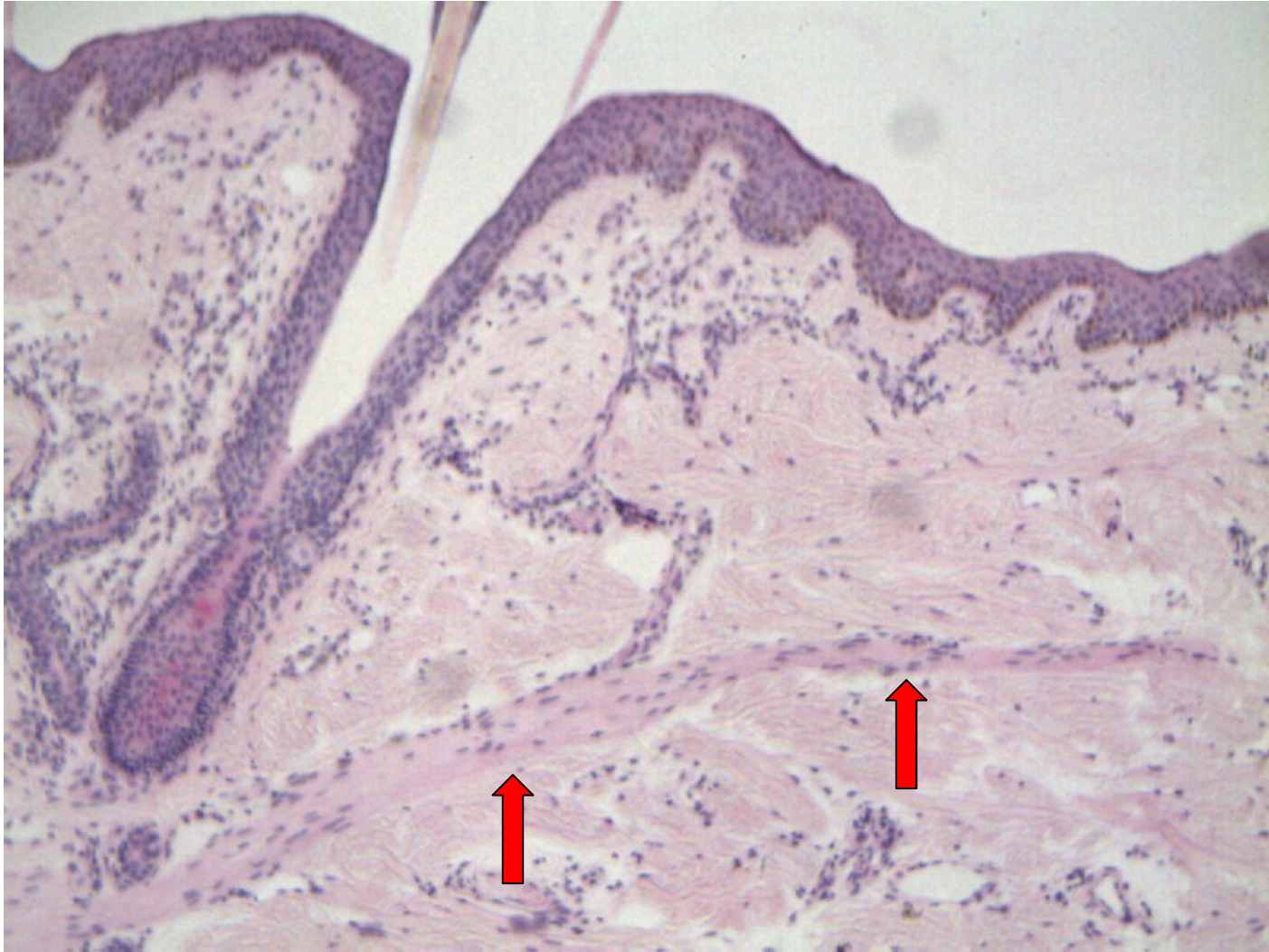
3. Smooth muscle

No.Ur3 Urinary bladder HE



3. Smooth muscle

No.Sk3 Scalp HE



Demonstration: scattered smooth muscle cells

Prostate HE

